

First Case of X-linked Recessive Anhidrotic Ectodermal Dysplasia with Immunodeficiency from Iran with Unusual *Aspergillus* Infection

Tooba Momen^{1*}, Abdolvahab Alborzi², Mohammad Hossein Eslamian³, Jean-Laurent Casanova⁴, and Capucine Picard^{5,6}

Received: 19 October 2019/ Accepted: 24 November 2019/ Published online: 22 December 2019

Abstract

NEMO (NF- κ B essential modulator) is a regulatory factor involved in signaling pathways of innate and adaptive immune system. Hypomorphic mutation of *IKBKG* gene on X chromosome leads to X-linked recessive anhidrotic ectodermal dysplasia with immunodeficiency.

* **Corresponding author:** Tooba Momen

E-mail: moment@sums.ac.ir

1. Department of Allergy and Clinical Immunology, Isfahan University of Medical Sciences, Isfahan, Iran

2. Clinical Microbiology Research Center, Shiraz University of Medical Sciences, Shiraz, Iran

3- Research Center for Immunodeficiencies, Pediatrics Center of Excellence, Children's Medical Center, Tehran University of Medical Sciences, Tehran, Iran

4. St Giles Laboratory of Human Genetics of Infectious Diseases, Rockefeller Branch, Rockefeller University, NY, USA

The affected boys presented developmental phenotype with hypotrichosis, hypohidrosis; hypodontia with conical incisors; and susceptibility to pyogenic bacteria, mycobacteria, and viruses. Most of them have impaired antibody response to polysaccharide antigens. Here, we presented the case report of 7 years old Iranian boy with NEMO-deficiency and unusual *Aspergillus* infection.

Keywords NF- κ B essential modulator essential modulator (NEMO), immunodeficiency, recurrent infections.

5. Laboratory of Human Genetics of Infectious Diseases, Necker Branch, INSERM U980, Necker Medical School, Paris Descartes University, Sorbonne Paris Cité, France.

6. Study Center for Primary Immunodeficiencies, AP-HP, Necker EnfantsMalades Hospital, Paris, France

Brief communication

X-linked anhidrotic ectodermal dysplasia with immunodeficiency (XL-EDA-ID) is considered as a rare congenital disease, which is characterized

by susceptibility to infectious diseases and abnormal development of ectoderm-derived skin appendages (1-5). Various hypomorphic mutations

have been found in nuclear factor-kappa B (NF- κ B) essential modulator (NEMO, also named *IKBKG*), which encodes a critical component of the NF- κ B signaling pathway (6-8).

(2, 9-11). XL-EDA-ID clinical (developmental and infectious susceptibility) and immunologic phenotypes are also highly mutation dependent, and previous reports showed the associations of specific mutations with particular phenotypes including susceptibility to poorly virulent mycobacteria, invasive pyogenic bacterial, and fungal and severe viral infections due to NF- κ B essential role in signaling both innate and adaptive immunity (3, 12-14). Both cellular and humoral abnormalities in XL-EDA-ID cases were recorded (15, 16). Most patients bearing NEMO mutations have an impaired antibody response, in particular that to glycans (17).

However, impairments in CD40-mediated B cell activation, isotype class switching, NK cell cytotoxicity, response to LPS stimulation, and production of TNF and IL-12 have been verified by in vitro studies conducted on some NEMO-deficient patients (14).

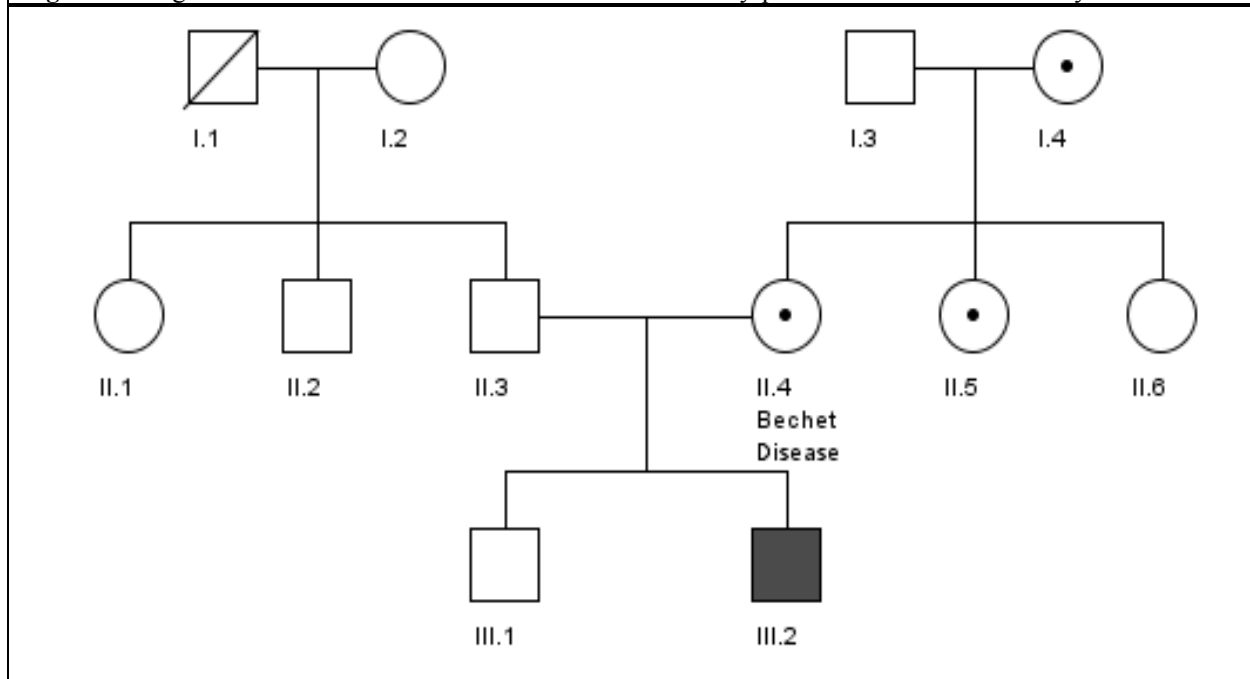
In this article, we presented a 7-year-old boy with XL-EDA-ID suffering from disseminated BCGitis and fungal infection with specific antibody deficiency against glycan antigens, as the first reported case with NEMO deficiency in Iran.

The patient was a boy born in 2006 to non-consanguineous parents with no history of immunodeficiency in his family. His mother has only a history of Behçet's disease (**Figure 1**). Birth growth parameters were normal, and he also had

normal mental development. . He received live polio virus vaccine and other live vaccine without any complication. Moreover, He developed diffused lymphadenopathy following Bacillus Calmette-Guérin (BCG) vaccination at the age of 3 days. At his first month of age, he was admitted to hospital due to having fever, dry cough, and respiratory distress; and diagnosis of pneumonia was made for him. During this admission, he showed abnormal movement such as fever, shaking in upper and lower extremities, and upward gaze. Cerebrospinal Fluid (CSF) analysis result was normal for him (CSF sugar: 36 mg/dl, CSF protein: 26 mg/dl, No cell was seen). Therefore, he was diagnosed with suspected febrile convulsion due to viral meningitis. During his first 9 months, he developed recurrent episodes of respiratory tract infection treated outpatient. Furthermore, he was in febrile status despite receiving antibiotic therapy.

At 9 months of age, he had another episode of disseminated BCGitis; despite regular anti-mycobacterial therapy. Physical examination revealed multiple cervical lymphadenopathies. Also, Biopsy of cervical nodes showed caseating granulomatous lymphadenitis. Spiral CT Scan of the abdomen showed enlarged liver with non-homogenous decreased parenchymal echogenicity without border forming mass lesion suggestive for infiltrative or inflammatory parenchymal disease.

Also, multiple para-aortic lymph nodes were demonstrated.

Figure1. Pedigree of X-linked Recessive Anhidrotic Ectodermal Dysplasia with Immunodeficiency

Also, multiple para-aortic lymph nodes were demonstrated. No abnormal finding was shown in bone marrow aspiration. He was treated with anti-mycobacterial therapy for 18 months according to disseminated BCGitis; and showed complete improvement after performing this process.

At the age of 3.5 years old, he was admitted to hospital for another time due to cough and lethargy. He was diagnosed with severe bronchopneumonia, and was treated with antimicrobial therapy lasted for 6 months. He had also another episode of pneumococcal pneumonia at the age of 4 years old. At the age of 5 years old, he experienced severe *Aspergillus nidulans* pneumonia, and was treated first with Voriconazole and then with Itraconazole for the duration of 1 year with favorable outcome. Furthermore, he reported an

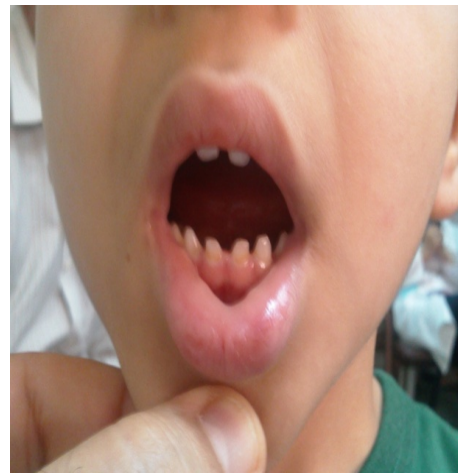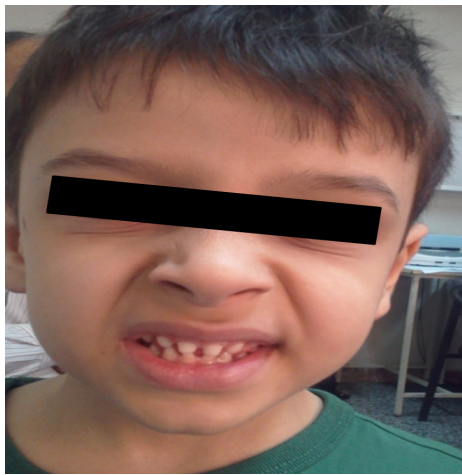episode of hematemesis, and diagnosis of peptic ulcer was made for his age and was resolved with conservative management and never repeated. The patient is now under well condition after completing the anti-mycobacterial therapy and covering by prophylactic dose of anti-fungal agents.

At the age of 6 years old, he was referred to Children's Medical Center Hospital for further evaluation. Physical examination revealed some features of ectodermal dysplasia including conical lacteal teeth without agenesis, specific nails, sparse hair, and cutaneous abnormalities (**Figure 2**). However, he had no evidences for hypohidrosis or osteopetrosis. By deep investigating the case, the parent's revealed that he had first tooth eruption at the age of 4 years old. Consequently, due to the mentioned problems associated with recurrent opportunistic and

unusual infections, a laboratory evaluation was performed as follows: Normal immunoglobulin levels (IgG=11.31 g/l, IgA= 1.40 g/l, IgM= 0.47 g/l), impaired response to pneumococcus vaccine, and defective response to PPD skin test (**Table 1**). Molecular genetic analysis revealed homozygous

NEMO mutation in the patient who carried a missense mutation in exon 8, c.932 A>G, which resulted in the substitution of asparagine by glycine at the residue 311 (designated D311G). Molecular testing of his mother, grandmother, and second aunt revealed heterozygous mutation.

Figure 2. Conical teeth and sparse hair of X-linked Recessive Anhidrotic Ectodermal Dysplasia with Immunodeficiency



Hypomorphic mutations in *NEMO* are associated with XL-EDA-ID. Patients with hypomorphic hemizygous *IKBKG* mutation appear to possess at least some variety of ID, regardless of presence or absence of EDA (2-5). However, this immunodeficiency is quite variable and may result from defects in signaling through the T-cell receptor, B- cell receptor, NK cell receptors, TLRs, CD40, and other TNF superfamily receptors, which all are downstream of NF- κ B (18, 19). Here in this study, we described the first Iranian patient with *NEMO* deficiency displaying a classical EDA phenotype, developed disseminated BCGitis, and pulmonary Aspergillosis. The patient has hemizygous *NEMO* mutation, and D311G was already reported in another patient (19). This mutation has been shown

to affect the polyubiquitin binding of *NEMO*, instead of *NEMO* expression and folding (19). The previously reported patient displayed also recurrent mycobacterial infection (*M. avium* and *M. abscessus*); however he did not developed fungal infection. The mycobacterial susceptibility in both patients can be explained by the impairment of IL-12 production, which was shown for the previously reported patient (19). The mechanism underlying this susceptibility involves the impairment of CD40-dependent IL-12 production (20). Defect in PPD skin test of our patient is the only document, which revealed that his cellular immune system failure led to disseminated BCGitis.

Although the function of innate immune and subsequent inflammatory reactions response of

macrophages to fungi are not well clarified totally, the importance of Toll/interleukin-1 receptor-like

domain-containing receptor yeast cell wall zymosan component was explained earlier.

Table 1. Immunologic characteristics of patient with X-linked Recessive Anhidrotic Ectodermal Dysplasia with Immunodeficiency

Parameters	Results
Complete Blood Count	9850
WBC (cells/ml)	5000
Lymphocyte (cells/ml)	64.9%
CD3+ T cells (% of Lymphocytes)	44.35%
CD3+CD4+ CD3+ T cells (% of Lymphocytes)	17.3%
CD3+ CD8+ T cells (% of Lymphocytes)	7.51%
CD16+ NK cells (% of Lymphocytes)	21.22%
CD19+ B cells (% of Lymphocytes)	
Serum Immunoglobulins	
IgG(mg/dl)	1131
IgA(mg/dl)	140
IgM(mg/dl)	47
IgE(IU/dl)	0.9
Vaccine-specific serology	
Anti-Tetanus (IU/ml)	0.5
Anti-Diphtheria (IU/ml)	0.7
Anti-Pneumonia Ab (IgG) before vaccination (µg/ml)	10.1
Anti-Pneumonia Ab (IgG) after vaccination (µg/ml)	11.1
Anti-Pneumonia Ab (IgG2) before vaccination (µg/ml)	2.5
Anti-Pneumonia Ab (IgG2) after vaccination (µg/ml)	4.5
T cell proliferations	
Phytohemagglutinin (PHA)	Normal
Dihydroamine reduction (DHR)	Normal
Tuberculosis Skin Test (PPD)	Defective

Abbreviations: WBC; white blood cells, Ig; Immunoglobulins, CD; Cluster of Differentiation

Presence of *Aspergillus* infection, which is the rare complication in NEMO deficiency (21, 22), in the current case could be interpreted with downstream defect in intracellular signaling of MyD88 pathways in response to zymosan, especially to (1→3)-β-D-glucans (5, 23).

Their immunological phenotypes are comparable, because both patients displayed the same impaired antibody response to glycans, as the only detected immunologic abnormality (19). Almost all patients bearing mutations in NEMO have an impaired antibody response, to glycans, including pneumococcal capsules, in particular (3, 4). Half of

them have also hypogammaglobulinemia, probably secondary to CD40 signaling impairment (Hanson et al., 2008). Some mutations in *IKBKG* gene are associated with T-cell defects, because NEMO is an essential component of the inhibitor of NF-κB (IκB)-kinase (IKK) complex affecting the phosphorylation of IκB, which is necessary for nuclear translocation of NF-κB [24]. Signaling through the IKK complex has been shown to be essential for the production of mature/memory T-cells, which may be considered as an explanation for the low memory T-cell phenotype observed in these patients (25, 26).

Lastly, regarding the developmental phenotype, the patient reported here indicated a more severe EDA phenotype (dysmorphic conical lacteal), compared to the patient with the same hemizygous *NEMO* mutation who was already reported to have only teeth agenesis of his maxillary lateral incisors and premolars (19). Thus, appropriate genetic diagnosis and genetic counseling appear to be essential, and testing for *NEMO* carrier should be considered if it is applicable as performed in our case for patient's mother and maternal aunts. Intravenous Immunoglobulins is the treatment of choice in *NEMO*-deficient patient with evidence of impaired antibody production. High incidence of atypical mycobacterial diseases infection in these cases is the essence need of prophylaxis. Prophylaxis against pneumocystis pneumonia should also be considered, specifically in boys with low T-cell counts or severely impaired lymphocyte proliferation (27). In conclusion, paying attention to gender, pattern of infections, and skin involvements of this case helped us to definite diagnosis and appropriate management.

Acknowledgments

We thank the patient and his family for their trust and cooperation. We thank Maya Chrahib and Virginie Grandin for technical assistance.

Conflicts of interest: The authors declare that they have no conflicts of interest.

References

1. Clarke A, Phillips DI, Brown R, Harper PS. Clinical aspects of X-linked hypohidrotic

ectodermal dysplasia. *Archives of disease in childhood*. 1987;62(10):989-96.

2. Doffinger R, Smahi A, Bessia C, Geissmann F, Feinberg J, Durandy A, et al. X-linked anhidrotic ectodermal dysplasia with immunodeficiency is caused by impaired NF-kappaB signaling. *Nature genetics*. 2001;27(3):277-85.

3. Hanson EP, Monaco-Shawver L, Solt LA, Madge LA, Banerjee PP, May MJ, et al. Hypomorphic nuclear factor-kappaB essential modulator mutation database and reconstitution system identifies phenotypic and immunologic diversity. *The Journal of allergy and clinical immunology*. 2008;122(6):1169-77 e16.

4. Puel A, Picard C, Ku CL, Smahi A, Casanova JL. Inherited disorders of NF-kappaB-mediated immunity in man. *Current opinion in immunology*. 2004;16(1):34-41.

5. Picard C, Casanova JL, Puel A. Infectious diseases in patients with IRAK-4, MyD88, NEMO, or IkappaBalpha deficiency. *Clinical microbiology reviews*. 2011;24(3):490-7.

6. Zonana J, Elder ME, Schneider LC, Orlow SJ, Moss C, Golabi M, et al. A novel X-linked disorder of immune deficiency and hypohidrotic ectodermal dysplasia is allelic to incontinentia pigmenti and due to mutations in IKK-gamma (NEMO). *American journal of human genetics*. 2000;67(6):1555-62.

7. Aradhya S, Woffendin H, Jakins T, Bardaro T, Esposito T, Smahi A, et al. A recurrent deletion in the ubiquitously expressed NEMO (IKK-gamma) gene accounts for the vast majority of incontinentia pigmenti mutations. *Human molecular genetics*. 2001;10(19):2171-9.

8. Mansour S, Woffendin H, Mitton S, Jeffery I, Jakins T, Kenwrick S, et al. Incontinentia pigmenti in a surviving male is accompanied by hypohidrotic ectodermal dysplasia and recurrent infection. *American journal of medical genetics*. 2001;99(2):172-7.
9. Jain A, Ma CA, Liu S, Brown M, Cohen J, Strober W. Specific missense mutations in NEMO result in hyper-IgM syndrome with hypohidrotic ectodermal dysplasia. *Nature immunology*. 2001;2(3):223-8.
10. Drogemuller C, Distl O, Leeb T. X-linked anhidrotic ectodermal dysplasia (ED1) in men, mice, and cattle. *Genetics, selection, evolution : GSE*. 2003;35 Suppl 1:S137-45.
11. Kobiela A, Kobiela K, Wisniewski SA, Midro AT, Trzeciak WH. Sequence polymorphisms of the EDA and the DL genes in the patients with an X-linked and an autosomal forms of anhidrotic ectodermal dysplasia. *Folia histochemica et cytobiologica / Polish Academy of Sciences, Polish Histochemical and Cytochemical Society*. 2001;39(2):113-4.
12. Cluzeau C, Hadj-Rabia S, Jambou M, Mansour S, Guigue P, Masmoudi S, et al. Only four genes (EDA1, EDAR, EDARADD, and WNT10A) account for 90% of hypohidrotic/anhidrotic ectodermal dysplasia cases. *Human mutation*. 2011;32(1):70-2.
13. Niehues T, Reichenbach J, Neubert J, Gudowius S, Puel A, Horneff G, et al. Nuclear factor kappaB essential modulator-deficient child with immunodeficiency yet without anhidrotic ectodermal dysplasia. *The Journal of allergy and clinical immunology*. 2004;114(6):1456-62.
14. Orange JS, Jain A, Ballas ZK, Schneider LC, Geha RS, Bonilla FA. The presentation and natural history of immunodeficiency caused by nuclear factor kappaB essential modulator mutation. *The Journal of allergy and clinical immunology*. 2004;113(4):725-33.
15. Abinun M, Spickett G, Appleton AL, Flood T, Cant AJ. Anhidrotic ectodermal dysplasia associated with specific antibody deficiency. *European journal of pediatrics*. 1996;155(2):146-7.
16. Schweizer P, Kalhoff H, Horneff G, Wahn V, Diekmann L. [Polysaccharide specific humoral immunodeficiency in ectodermal dysplasia. Case report of a boy with two affected brothers]. *Klinische Padiatrie*. 1999;211(6):459-61.
17. Dupuis-Girod S, Corradini N, Hadj-Rabia S, Fournet JC, Faivre L, Le Deist F, et al. Osteopetrosis, lymphedema, anhidrotic ectodermal dysplasia, and immunodeficiency in a boy and incontinentia pigmenti in his mother. *Pediatrics*. 2002;109(6):e97.
18. Keller MD, Petersen M, Ong P, Church J, Risma K, Burham J, et al. Hypohidrotic ectodermal dysplasia and immunodeficiency with coincident NEMO and EDA mutations. *Frontiers in immunology*. 2011;2:61.
19. Hubeau M, Ngadjeua F, Puel A, Israel L, Feinberg J, Chrabieh M, et al. New mechanism of X-linked anhidrotic ectodermal dysplasia with immunodeficiency: impairment of ubiquitin binding despite normal folding of NEMO protein. *Blood*. 2011;118(4):926-35.
20. Stark R, Hartung A, Zehn D, Frentsch M, Thiel A. IL-12-mediated STAT4 signaling and TCR signal strength cooperate in the induction of CD40L

in human and mouse CD8⁺ T cells. *European journal of immunology*. 2013;43(6):1511-7.

21. Kawai T, Nishikomori R, Izawa K, Murata Y, Tanaka N, Sakai H, et al. Frequent somatic mosaicism of NEMO in T cells of patients with X-linked anhidrotic ectodermal dysplasia with immunodeficiency. *Blood*. 2012;119(23):5458-66.

22. Nishikomori R, Akutagawa H, Maruyama K, Nakata-Hizume M, Ohmori K, Mizuno K, et al. X-linked ectodermal dysplasia and immunodeficiency caused by reversion mosaicism of NEMO reveals a critical role for NEMO in human T-cell development and/or survival. *Blood*. 2004;103(12):4565-72.

23. Kataoka K, Muta T, Yamazaki S, Takeshige K. Activation of macrophages by linear (1right-arrow3)-beta-D-glucans. Implications for the recognition of fungi by innate immunity. *The Journal of biological chemistry*. 2002;277(39):36825-31.

24. Orange JS, Levy O, Geha RS. Human disease resulting from gene mutations that interfere with appropriate nuclear factor-kappaB activation. *Immunological reviews*. 2005;203:21-37.

25. Schmidt C, Peng B, Li Z, Sclabas GM, Fujioka S, Niu J, et al. Mechanisms of Proinflammatory Cytokine-Induced Biphasic NF-@kB Activation. *Mol Cell*. 2003;12(5):14-.

26. Schmidt-Supprian M, Courtois G, Tian J, Coyle AJ, Israel A, Rajewsky K, et al. Mature T cells depend on signaling through the IKK complex. *Immunity*. 2003;19(3):377-89.

27. Orange JS, Brodeur SR, Jain A, Bonilla FA, Schneider LC, Kretschmer R, et al. Deficient natural killer cell cytotoxicity in patients with IKK-gamma/NEMO mutations. *The Journal of clinical investigation*. 2002;109(11):1501-9.