

Unique Presentation of Common Variable Immunodeficiency: Enteropathy Unaccompanied by Infectious Phenotype

Nasser Ebrahimi Daryani^{1*}, Babak Torabi-Sagvand², Elnaz Panah²

Received: 04 January 2019/ Accepted: 18 February 2019/ Published online: 22 March 2019

Abstract

Enteropathy is one of the rare manifestations of common variable immunodeficiency (CVID) as a predominant antibody deficiency. Proper diagnosis of this phenotype in CVID cases is difficult and may result in inaccurate assessment or incorrect management.

Further, this misdiagnosis is more probable when noninfectious diarrhea is the only manifestation of CVID. We present herein a case with such an abstruse condition who was misdiagnosed as a celiac disease leading to delayed diagnosis of her primary immunodeficiency disease. We also offer a review on enteropathy manifestation in CVID patients.

* **Corresponding author:** Nasser Ebrahimi Daryani

E-mail: nebrahim@sina.tums.ac.ir

1. Department of Gastroenterology and Hepatology, Imam Khomeini Hospital, Tehran University of Medical Sciences, Tehran, Iran

2. Research Center for Immunodeficiencies, Pediatrics Center of Excellence, Children's Medical Center, Tehran University of Medical Sciences, Tehran, Iran

Keywords Gastrointestinal manifestation, Enteropathy phenotype, Common variable immunodeficiency, Diagnostic delay

Introduction

Common variable immunodeficiency (CVID) as the most prevalent symptomatic primary immunodeficiency disease (PID) comprises a heterogeneous group of disorders characterized by hypogammaglobulinemia, defective specific

antibody production, and increased susceptibility to recurrent and chronic infections (1, 2).

CVID affects both adults and children with a prevalence between 1 per 10,000 and 1 per 50,000 inhabitants. This disease may present at any point

in a patient's lifetime, although the 2 major peaks of onset are childhood (5-10 years of age) and the third decade (3).

Four major clinical phenotypes of CVID have been described including only infectious disease, autoimmunity, polyclonal lymphocytic infiltration, and enteropathy (4-6). Three former phenotypes are always accompanied by some history of recurrent infection. A total of 83% of patients have only one of these phenotypes and the remaining patients may present with overlapped syndromes of autoimmune disorder, enteropathy, and lymphoproliferative disorders.

CVID-related enteropathy is determined by biopsy-proven lymphocytic infiltration in lamina propria and interepithelial mucous with villous atrophy insensitive to gluten withdrawal. Presence of recurrent or chronic infections in medical history of the patient may help physicians to diagnosis the PID in cases with manifestation of non-infectious only phenotypes. This article introduces a CVID case who suffered CVID-related enteropathy as the single presentation of CVID without any significant episode of infection.

Case report

A 31-year-old woman referred to our center with a chief complaint of persistent diarrhea and weight loss. She is the second child of consanguineous parents (first cousins) with no family history of PID. She had been suffering repeated semi-solid diarrheas accompanied by abdominal cramps since she was 26. After all available GI work-ups,

gluten-free diet had been established due to suspicion of celiac sprue; however, no improvement was achieved. Her symptoms had deteriorated for 2 months before referral. She lost 10-kilograms during only 1 month. Then, she had been referred to the gastroenterology and liver (GI) disease of our referral center. In physical examination, the patient was a cachectic woman with no other abnormal findings except for a vitiligo patch on the right side of her face. Comprehensive evaluation was started for her with some of the laboratory findings listed in **Table 1**.

Stool exam was completely normal and its culture was also negative for known pathogens. Other common GI disorders such as GI cancers and celiac sprue were ruled out, based on several investigations such as upper GI endoscopy, colonoscopy-biopsy, HLA typing, and small bowel series. Serial section biopsy specimens from different parts of jejunum mucosa showed mild to moderate villous atrophy (**Figure 1**). Villous height to crypt depth ratio was 2-3/1. Mild intraepithelial lymphocyte infiltration (35 per 100 enterocytes) especially at the tip of some villi was also reported.

Focal cytoplasmic vacuolization in some epithelial cells was observed at the tip of a few intestinal villi. Intestinal glands were unremarkable. No microorganism especially *Giardia* was seen in any of the biopsies.

Mucosa associated lymphoid cells showed mild increase only in some areas and composed of the typical number of plasma cells and B-lymphocytes with mild increase in the number of T-cells. Immunohistochemistry studies were performed

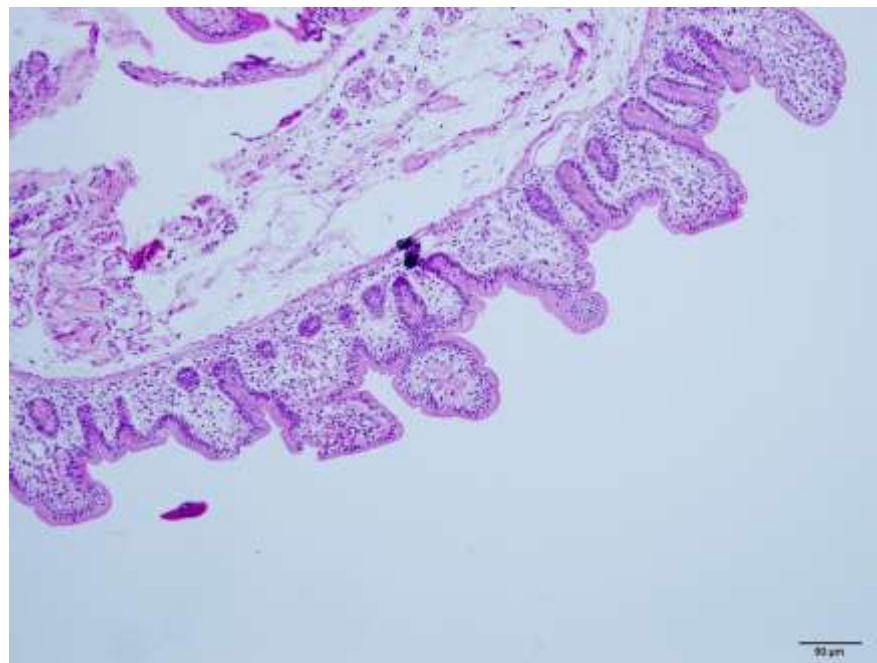
using anti-human antibodies against the following markers where the results were as follows: Positive for CD138 in the usual plasma cells of lamina propria, positive for CD20 in a number of

scattered and one lymphoid aggregate in lamina propria, and positive for CD3 in majority of lymphocytes of lamina propria, and the intraepithelial lymphocytes.

Table 1. Immunologic characteristics of the patient with X-linked Recessive Anhidrotic Ectodermal Dysplasia with Immunodeficiency

Parameters	Results
Complete Blood Count	
WBC (cells/ml)	8100
Lymphocyte (cells/ml)	1944
Neutrophils (cells/ml)	5913
CD3+ T cells (% of Lymphocytes)	88.2%
CD3+CD4+ CD3+ T cells (% of Lymphocytes)	63.5%
CD3+ CD8+ T cells (% of Lymphocytes)	29.2%
CD16+ NK cells (% of Lymphocytes)	8.4%
CD19+ B cells (% of Lymphocytes)	2.1%
CD20+ B cells (% of Lymphocytes)	2.2%
Serum Immunoglobulins	
IgG (mg/dl)	331
IgA (mg/dl)	19
IgM (mg/dl)	39
IgE (IU/dl)	1
Vaccine-specific serology	
Anti-Tetanus (IU/ml)	0.5
Anti-Diphtheria (IU/ml)	0.7
Anti-Pneumonia Ab (IgG) before vaccination ($\mu\text{g/ml}$)	10.1
Anti-Pneumonia Ab (IgG) after vaccination ($\mu\text{g/ml}$)	131.9
Anti-Pneumonia Ab (IgG2) before vaccination ($\mu\text{g/ml}$)	2.5
Anti-Pneumonia Ab (IgG2) after vaccination ($\mu\text{g/ml}$)	45.2

Figure 1. Jejunal section biopsy of the patient with CVID presenting enteropathy



Finally, the patient was referred to our center for immunologic assessment. Decreased levels of immunoglobulins and lymphocyte subset analysis (Table 1) were strongly suggestive for CVID. So, intravenous immunoglobulin (IVIG) was initiated once a month, but her symptoms did not ameliorate. Finally, oral prednisolone, significantly improved her symptoms, and even caused five kilograms weight gain in 2 months.

Discussion

The main gastrointestinal manifestation of CVID is transient or persistent diarrhea, found in 21–57% of subjects especially due to viral infections (7). Other intestinal manifestations include chronic giardiasis amebiasis, intestinal malabsorption, and atrophic gastritis with pernicious anemia. On the other hand, about 20% of patients with CVID have GI symptoms without any infectious cause and 10% develop idiopathic malabsorption associated with weight loss. Differentiating between diarrheas of infectious or inflammatory origin is difficult (8, 3).

CVID-related enteropathy characterized as biopsy-proven lymphocytic infiltration in lamina propria and interepithelial mucous with villous atrophy (6), grossly resembles celiac sprue if this symptom is isolated without any association with other sites recurrent infection (9). Symptoms of CVID-related enteropathy range from mild discomfort, bloating, and diarrhea to more severe profuse diarrhea, malabsorption, and weight loss (7). There are two types of enteropathy, one exclusively affecting the large bowel and the other

predominantly affecting small bowel with malabsorption (10). Although small-bowel biopsy often shows villous atrophy and crypt hyperplasia, similar to the findings in celiac disease, several key differences are apparent between the villous flattening of CVID and classic celiac sprue. In classic celiac sprue, there is plasma cell infiltration accompanied by elevated levels of IgM and IgA. Diminished antibody production in CVID makes this unable to be the cause of villous flattening (11-13). Very little is known on the pathophysiology of CVID-related enteropathy. It is believed that it may be related to increased apoptosis, decreased plasma cells, and increased tumor necrosis factor alpha (TNF α), as shown in the histology of some patients to produce T lymphocyte dysfunction (12-14). In addition, none of the pathognomonic antibodies of classic celiac sprue (antigliadin, antireticulin, or anti-endomysial antibodies) are present in CVID cases with enteropathy. Another key difference is the role of gluten. In classic celiac sprue, gluten-free diet almost always leads to recovery of normal villous architecture. However, in CVID, it does not improve villous flattening (15).

Several CVID-related enteropathy cases have been reported previously. However, observing enteropathy as an unaccompanied presentation of CVID especially without any episodes of infections makes this case somehow outstanding. Basically, multiple organ involvement is a characteristic feature of PIDs due to propagation of immune system. Involvement of a single organ strongly suggests anatomical or functional

disorders. However, other probable conditions must also be taken into consideration. In the current case, persistent diarrhea was the first and the single presentation of CVID. Meanwhile, CVID and recurrent infections are considered to be closely related. Nevertheless, the introduced case had had no history of recurrent or chronic infections yet. So, presence of recurrent infection is not an unavoidable criterion for diagnosis, at least in the preliminary presentation of disease. Consequently, persistent diarrhea even with no history of recurrent infections can be the sole presentation of CVID.

Mainstay treatment for CVID is replacement therapy with intravenous or subcutaneous human immunoglobulin (16), along with antibiotics for infections and appropriate treatment for the noninfectious complications (17). The treatment of enteropathy in CVID patients is usually symptomatic. Treatment with intravenous IgG typically does not affect the CVID-related enteropathy (18). Many patients respond to budesonide and prednisolone. However, considerable side effects during long-term treatment limit its use (8). The aim of steroid therapy is to reduce the inflammatory response. We could not continue IVIG therapy for the case # 2 because of allergic reaction, while IVIG could not improve the CVID-related enteropathy in the first case, despite continuous and regular full dose infusion. The lack of response to IVIG accentuates the theory of T-cell dysfunction in CVID-related enteropathy. Then, we could successfully treat her with oral prednisolone, without any significant

side effects. We continued IVIG infusion to improve immunoglobulin levels, and to prevent probable infectious complications of corticosteroids.

The use of intravenous IL-2 replacement has been considered since the discovery of IL-2 deficiency in CVID. Improvement in T-cell function and formation of atypical antibodies has been observed, but no patient has been placed into complete remission. IL-2 replacement is viewed as an adjunctive therapy to intravenous IgG.

Conclusion

CVID could present without any history of recurrent bacterial infections, involving a single organ, especially GI tract, which takes a long time to be diagnosed. CVID-related enteropathy does not respond to human immunoglobulin replacement therapy, and can be treated by oral corticosteroids.

Conflicts of interest: The authors declare that they have no conflicts of interest.

References

1. Aghamohammadi A, Farhoudi A, Moin M, Rezaei N, Kouhi A, Pourpak Z et al. Clinical and immunological features of 65 Iranian patients with common variable immunodeficiency. *Clinical and diagnostic laboratory immunology*. 2005;12:825-32..
2. Aghamohammadi A, Parvaneh N, Rezaei N. Common variable immunodeficiency: a heterogeneous group needs further

- subclassification. Expert review of clinical immunology. 2009;5:629-31.
3. Khodadad A, Aghamohammadi A, Parvaneh N, Rezaei N, Mahjoob F, Bashashati M et al. Gastrointestinal manifestations in patients with common variable immunodeficiency. Digestive diseases and sciences. 2007;52:2977-83.
 4. Aghamohammadi A, Abolhassani H, Moazzami K, Parvaneh N, Rezaei N. Correlation between common variable immunodeficiency clinical phenotypes and parental consanguinity in children and adults. Journal of investigational allergology & clinical immunology. 2010;20:372-9.
 5. Chapel H, Cunningham-Rundles C. Update in understanding common variable immunodeficiency disorders (CVIDs) and the management of patients with these conditions. British journal of haematology. 2009;145:709-27.
 6. Chapel H, Lucas M, Lee M, Bjorkander J, Webster D, Grimbacher B et al. Common variable immunodeficiency disorders: division into distinct clinical phenotypes. Blood. 2008;112:277-86.
 7. Patel J, Kumar A, Agasti A, Choksey A, Phadke A, Sawant P. CVID enteropathy- a rare cause of chronic diarrhea in a child. Indian journal of pediatrics. 2012;79:1374-6.
 8. Lai Ping So A, Mayer L. Gastrointestinal manifestations of primary immunodeficiency disorders. Seminars in gastrointestinal disease. 1997;8:22-32.
 9. Luzi G, Zullo A, Iebba F, Rinaldi V, Sanchez Mete L, Muscaritoli M et al. Duodenal pathology and clinical-immunological implications in common variable immunodeficiency patients. The American journal of gastroenterology. 2003;98:118-21.
 10. Teahon K, Webster AD, Price AB, Weston J, Bjarnason I. Studies on the enteropathy associated with primary hypogammaglobulinaemia. Gut. 1994;35:1244-9.
 11. Daniels JA, Lederman HM, Maitra A, Montgomery EA. Gastrointestinal tract pathology in patients with common variable immunodeficiency (CVID): a clinicopathologic study and review. The American journal of surgical pathology. 2007;31:1800-12.
 12. Kalha I, Sellin JH. Common variable immunodeficiency and the gastrointestinal tract. Current gastroenterology reports. 2004;6:377-83.
 13. Tahan V, Dobrucali A, Canbakan B, Hamzaoglu I, Ozaras R, Biyikli M et al. Cytomegalovirus infection of gastrointestinal tract with multiple ulcers and strictures, causing obstruction in a patient with common variable immunodeficiency syndrome. Digestive diseases and sciences. 2000;45:1781-5.
 14. Aukrust P, Lien E, Kristoffersen AK, Muller F, Haug CJ, Espevik T et al. Persistent activation of the tumor necrosis factor system in a subgroup of patients with common variable immunodeficiency--possible immunologic and

- clinical consequences. *Blood*. 1996;87:674-81.
15. Heneghan MA, Stevens FM, Cryan EM, Warner RH, McCarthy CF. Celiac sprue and immunodeficiency states: a 25-year review. *Journal of clinical gastroenterology*. 1997;25:421-5.
16. Oksenhendler E, Gerard L, Fieschi C, Malphettes M, Mouillot G, Jaussaud R et al. Infections in 252 patients with common variable immunodeficiency. *Clinical infectious diseases: an official publication of the Infectious Diseases Society of America*. 2008;46:1547-54.
17. Malamut G, Verkarre V, Suarez F, Viallard JF, Lascaux AS, Cosnes J et al. The enteropathy associated with common variable immunodeficiency: the delineated frontiers with celiac disease. *The American journal of gastroenterology*. 2010;105:2262-75.
18. Cordova Guevara H, Guarner Aguilar L. Effective treatment of common variable immunodeficiency associated diarrhea. *Revista espanola de enfermedades digestivas: organo oficial de la Sociedad Espanola de Patologia Digestiva*. 2009;101:215-9.